



Chandra S Katragadda, MD, PA
Interventional & Diagnostic Radiology

Patricia H. Gallagher, MD
Mammography, Ultrasound & Diagnostic Radiology

Rudolph Alvarado, MD
Interventional & Diagnostic Radiology

Thomas W. Ertzner, MD
Nuclear Medicine & Diagnostic Radiology

R. Drake Beauchamp, MD
Abdominal Imaging & Diagnostic Radiology

Alexander T. Aitken, MD
Interventional & Diagnostic Radiology

Mukul P. Maheshwari, MD
Neuroradiology, Head/Neck & Diagnostic Radiology

D.C. Ayar, MD
Interventional & Diagnostic Radiology

Carlos R. Gutierrez, MD, PA
Nuclear Medicine, Body Imaging & Diagnostic Radiology

Kenneth S. Vanexan, MD
Neuroradiology, Head/Neck & Diagnostic Radiology

Anthony N. Hein, MD
Interventional & Diagnostic Radiology

Parina Gupta Cho, MD
Body Imaging & Diagnostic Radiology

D. Anthony Townsend, MD
Body Imaging & Diagnostic Radiology

Jennifer E. Turner, MD, PA
Body Imaging & Diagnostic Radiology

Matthew A. Comay, MD
Body Imaging & Diagnostic Radiology

Chien I. Yang, MD
Neuroradiology, Head/Neck & Diagnostic Radiology

Case of the Month: Posterior Labrocapsular Periosteal Sleeve Avulsion (Polpsa Lesion)

History: 46 year old female who had a history of fall on outstretched hand with shoulder pain, especially in adduction and internal rotation.

MRI Findings: The posterior labrum (arrow) is torn from the posterior glenoid and displaced posteriorly. The periosteum (arrowhead) is stripped from the posterior glenoid, but is still attached to the displaced labral tissue. The humeral head is posteriorly subluxed.

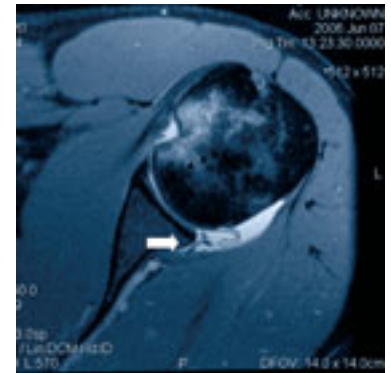
Diagnosis: Posterior periosteal sleeve avulsion (POLPSA) lesion with associated posterior glenohumeral instability.

Discussion of Posterior Labrocapsular Periosteal Sleeve Avulsion (Polpsa Lesion):

POLPSA lesion is avulsion of the posterior labroligamentous structures and periosteal sleeve from the posterior scapula. It differs from a reverse Bankart lesion because the periosteum, although detached, remains intact with the posterior capsule and detached posterior labrum. This lesion may represent an acute form of a Bennett lesion. Other associated injuries include subscapularis tendon tear and reverse Hill-Sachs or Trough fracture.

The POLPSA lesion is an abnormality that can be associated with posterior instability. Recurrent posterior subluxation is the most common form of

posterior instability. Instability in the patients with this lesion typically results from a single traumatic event or repetitive microtrauma. The most common traumatic event resulting in posterior instability is a posterior shoulder dislocation, such as in a fall on outstretched hand, seizure, electric shock, or direct trauma to the anterior shoulder. In atraumatic posterior instability there is no history of major trauma; however, there is almost always repetitive microtrauma causing labral pathology and posterior capsular stretching. Patients who are at risk for posterior instability include athletes such as weight lifters, throwers, tennis players, and swimmers.



Meet Dr. Emily Lee

Dr. Emily H. Lee attended the University of California, Berkeley undergraduate program; later, she graduated from the University of Texas Health Science Center at San Antonio School of Medicine. Following her internship at

UCSF-Fresno Medical Center, she completed her diagnostic radiology residency at Indiana

University. She then finished one year of musculoskeletal radiology fellowship under the tutelage of Dr. Donald Resnick at the University of California, San Diego.

Dr. Lee is a member of the American Board of Radiology, the Radiological Society of North America, and the American Roentgen Ray Society, where she has presented exhibits entitled "MR Imaging of the Knee: Preference of Orthopedic Surgeons," "Injuries to the extensor mechanism of the knee: MRI findings and treatment implication," and "Cardiac leads and beyond."





Visit us online at
www.radiologyimaging.com

We Welcome your
feedback and sugges-
tions about this news-
letter and our services.

Please call us at
(361) 853-4503 ext.55

Alameda Imaging Center

3226 S. Alameda St.
Corpus Christi, TX 78404
(361) 888-6684

Williams Imaging Center

7101 Williams Dr.
Corpus Christi, TX 78412
(361) 993-9393

Coastal Bend P.E.T. Scan, Ltd.

1533 5th St.
Corpus Christi, TX 78404
(361) 880-SCAN (7226)
(361) 881-6252 Fax

Central Scheduling

To schedule an exam, please call:
(361) 888-8875

Business Office

3226 Reid Dr.
Corpus Christi, TX 78404
(361) 853-4503
(361) 853-4454 Fax



RADIOLOGY & IMAGING
OF SOUTH TEXAS, L.L.P.

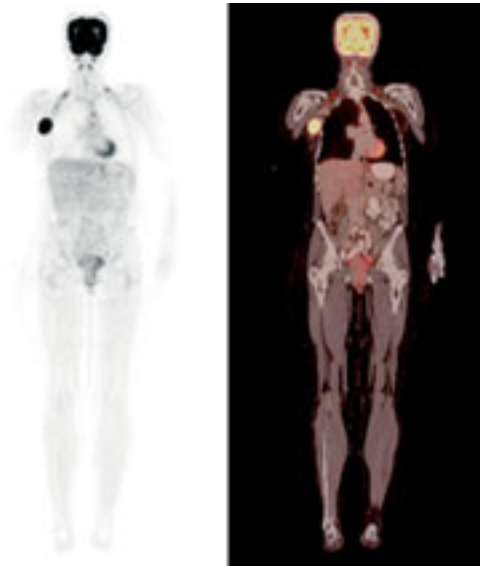PET/CT: Melanoma - 47-year-old female

History

47-year-old female with a six-year history of mole noted on her back in the right subscapular area. The lesion was black in color with irregular borders and with cauliflower like growth. The area was initially accidentally scratched with subsequent bleeding and followed by noticeable growth. Progressive enlargement of right axilla lymph node within 5 to 6 months. A core biopsy was obtained of axillary lymph node where the pathology was positive for high grade large cell malignant neoplasm, consistent with metastatic malignant melanoma.

2/18/05 Mammogram

3cm right axillary lesion, no suspicious lesions or microcalcifications noted in her breasts.



2/18/05 Ultrasound

Right axillary solid mass 4.8 cm in largest dimension.

3/2/05 Core bx Findings

High grade large cell malignant melanoma within the right axillary lymph node.

3/8/05 Reason for PET/CT

This is a 47 year old female newly diagnosed with stage III metastatic melanoma via axillary biopsy, referred for initial staging.

PET/CT Findings

Intense hypermetabolic right back and right axillary focal activity, compatible with known malignancy. Asymmetrically increased left uterine cervical activity is nonspecific. Further evaluation is recommended if indicated.

Treatment

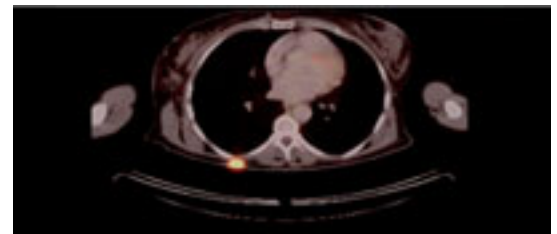
Wide local excision melanoma right upper back and right axillary lymph node dissection.

Dosage

10.3 mCi F18-FDG

Courtesy of

University of Tennessee Medical Center
David Townsend



Funny Bones

Shortly after the 911 emergency number became available, an elderly, and quite ill lady appeared in a Texas hospital emergency room, having driven herself to the hospital and barely managing to stagger in from the parking lot.

The horrified nurse said, "Why didn't you call the 911 number and get an ambulance?"

The lady said, "My phone doesn't have an eleven."



Batting For a Cure

The American Cancer Society Relay for Life was held on July 28, 2006 at Whataburger Field. Radiology & Imaging was one of the teams "Batting for a Cure." What a great experience for all of us. Our team of 59 employees, raised well over \$13,000 through various fund raising events and the generous support of our vendors.

Radiology & Imaging of South Texas was also the very proud Educational Sponsor for five of the Coastal Bend Relays this year. We hope that many of you will join us next year with a team as we keep fighting to find a cure for this vicious disease.