



Chandra S Katragadda, MD, PA
Interventional & Diagnostic Radiology

Patricia H. Gallagher, MD
Mammography, Ultrasound &
Diagnostic Radiology

Rudolph Alvarado, MD
Interventional & Diagnostic Radiology

Thomas W. Ertzner, MD
Nuclear Medicine & Diagnostic Radiology

R. Drake Beauchamp, MD
Abdominal Imaging & Diagnostic Radiology

Alexander T. Aitken, MD
Interventional & Diagnostic Radiology

Mukul P. Maheshwari, MD
Neuroradiology, Head/Neck & Diagnostic
Radiology

D.C. Ayar, MD
Interventional & Diagnostic Radiology

Carlos R. Gutierrez, MD, PA
Nuclear Medicine, Body Imaging
& Diagnostic Radiology

Kenneth S. Vanexan, MD
Neuroradiology, Head/Neck & Diagnostic
Radiology

Anthony N. Hein, MD
Interventional & Diagnostic Radiology

Parina Gupta Cho, MD
Body Imaging & Diagnostic Radiology

D. Anthony Townsend, MD
Body Imaging & Diagnostic Radiology

Jennifer E. Turner, MD, PA
Body Imaging & Diagnostic Radiology

Matthew A. Comay, MD
Body Imaging & Diagnostic Radiology

Chien I. Yang, MD
Neuroradiology, Head/Neck & Diagnostic
Radiology

Grady Yoder, MD
Interventional Diagnostic Radiology

Digital Mammography Arrives

We are pleased to announce our new digital mammography system at Alameda Imaging Center. The digital mammogram replaces the traditional mammogram as the primary screening tool in detecting early breast cancer.

Digital mammography refers to how a picture of the breast is generated. The traditional mammogram uses an x-ray to generate an image on a piece of film. A digital mammogram uses x-ray to convert electrical signals into a computer image. The digital mammogram is performed in the same fashion as the traditional mammogram. As with traditional mammogram, compression of the breast is essential to spread tissues apart. Compression enhances the ability to visualize masses and other abnormalities while reducing radiation dose and motion.

Just as with your digital camera, the mammogram images can be viewed almost immediately. The technologist can determine if any repeat images are required for motion or position without having to wait to develop film in a processor.

As the images are displayed on a computer, the radiologist can manipulate the images for contrast and brightness. The computer also enables magnification of the images. This ability to post process the image may make finding breast cancer easier. Indeed, women under 50, premenopausal women, and a woman with

dense breast tissue benefit more from digital mammograms than traditional mammograms in a recent ongoing study. The digital mammogram enabled the radiologist to find more cancers in these individuals, probably due to the ability to manipulate the image.

The mammogram obtained with digital format is stored on a computer. The images can be sent over a computer to another location. Consultation with another radiologist or physician is just an email away!

Our state-of-the-art digital mammography system is digital mammography at it's very best.

- *It delivers the lowest possible dose.*
- *It has patient comfort features such as flexible paddles and a patented technique that senses breast thickness for a more comfortable compression.*
- *Helps increase cancer detection rates with Computer Assisted Diagnosis (CAD) markers.*
- *Largest detector, which allows imaging of almost all breast sizes.*
- *Excellent image quality.*
- *Latest full field detector technology based on amorphous selenium (a-SE)*
- *Increased detection of small and low contrast objects.*

If you and your patient are interested in scheduling a digital mammogram, please call:
[CENTRAL SCHEDULING AT 361-888-8875]



Meet Dr. Gallagher

Dr. Patricia Gallagher is a diplomate of the American Board of Radiology, and a diagnostic Radiologist who is sub-specialty trained in Mammography and Ultrasound. Dr. Gallagher earned

her medical degree from the University of Texas, Southwestern Medical School Dallas. She completed her residency at UT Health Science Center and V.A. Medical Center in San Antonio.

Dr. Gallagher earned a Fellowship in Ultrasound, Mammography, and Body CT at the UT Medical Branch in Galveston. She is a member of the American College of Radiology, American Roentgen Ray Society, Radiological Society of North America, and American Medical Assoc.

Dr. Gallagher and her husband Dr. Thomas Helms are the proud parents of two daughters. In her spare time she enjoys traveling, reading and being outdoors.





Visit us online at
www.radiologyimaging.com

We Welcome your
feedback and
suggestions about
this newsletter and
our services.

Please call us at
(361) 853-4503 ext.55

Alameda Imaging Center

3226 S. Alameda St.

Corpus Christi, TX 78404

(361) 888-6684

Williams Imaging Center

7101 Williams Dr.

Corpus Christi, TX 78412

(361) 993-9393

Coastal Bend P.E.T. Scan, Ltd.

1533 5th St.

Corpus Christi, TX 78404

(361) 880-SCAN (7226)

(361) 881-6252 Fax

Central Scheduling

To schedule an exam, please call:

(361) 888-8875

Business Office

3226 Reid Dr.

Corpus Christi, TX 78404

(361) 853-4503

(361) 853-4454 Fax

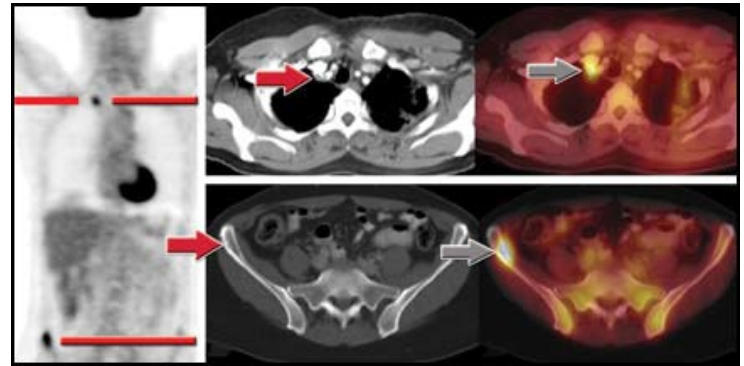


**RADIOLOGY & IMAGING
OF SOUTH TEXAS, L.L.P.**

Case of the Month

History

50 year old female, with history of breast cancer status post lumpectomy, chemotherapy. Patient presents with recurrence with positive biopsy of a supraclavical lymph node, but no other disease noted on CT alone. The patient was referred to the PET center for a PET/CT evaluation for radiation therapy.



Dosage

15m Ci F-18 FDG by IV

PET/CT Findings

Focal lesion posterior to the brachiocephalic vein consistent with metastatic disease. Intense area of focal uptake in the left iliac crest without an identifiable CT correlate. Findings are still consistent with with mestastic disease.

Discussion

This case is a good example of the added benefits of PET/CT. First, the patient had a subtle abnormality detected posterior to the brachiocephalic vein that is barely visible on CT, but is certainly very compelling on the fused PET/CT image. Secondly, the patient has a large lesion in the right iliac creat that is not visible on the CT portion of the exam. It is not uncommon to find a lesion on PET, localize it to bone using PET/CT, but realize there is no bony destruction yet.

Change in treatment plan

Treatment ws ultimately changed from local radiation to the supraclavical area to systemic chemotherapy.

Funny Bones Get to know our Radiologists.

Alexander Aitken	D Q L H H G N A Y N E I H C T R C B R R F
Jennifer Turner	R R N E K T I A R E D N A X E L A W Z R Q
Anthony Hein	A Z R U D O L P H A L V A R A D O R E K R
Kenneth Vanexan	K A R A N T H O N Y H E I N K X Y N D R L
Anthony Townsend	E N K T A M T H K P P K V N N P R K E N M
Matthew Comay	B T Q B D L X V G G T W V F J U T H N U M
Carlos Gutierrez	E H G D D P H T Z H F T N T T V G Y K E Z
Mukul Maheshwari	A O L M A F A Q F P R W R R K A V U V N E
Chandra Katragadda	U N R F G T H R B N L A E R L K L G A M R
Parina Cho	C Y M K A Y H Q I J P F Y L L M R X K M R
Chien Yang	H T R B R P J O G N I M A A A L E H A G E
Patricia Gallagher	A O M R T F K P M N A G J H E N N T D B I
Dave Ayar	M W W Q A W T H N A A C E G A V T N V D T
Rudoph Alvarado	P N K P K F M E J I S S H V H H A V M T U
Drake Beauchamp	X S M J A G J C C F H E H O E F V D Q K G
Thomas Ertzner	M E T P R T M I V W N T R W L D T W P X S
	X N L Z D V R R A H E N C T M Q W Z R T O
	R D N F N T X R N N L O W C Z K M W R D L
	X M K V A P I K N N M J B K W N N G N K R
	X N B P H F W E A A K R B R J L E B K G A
	Q G M Q C D K M Y Z M B T L N D J R M Z C